

THE EFFICACY OF AN INTRAOSSEOUS INJECTION SYSTEM OF DELIVERING LOCAL ANESTHETIC

MYER S. LEONARD, D.D.S., M.D.

More than 10 years ago, Kaufman, Weinstein and Milgrom reviewed many of the problems encountered in achieving successful anesthesia.¹ Since then, studies by Reader and colleagues have used electric pulp testing to assess the degree of anesthesia.^{2,4} These studies were limited in that the teeth studied were free of apical pathology. Also, the fact that a tooth is no longer sensitive to electrical stimulation cannot be taken to mean that a depth of anesthesia has been achieved that will permit pain-free extraction. Indeed, McLean and others found that among subjects who felt numb following administration of an inferior or alveolar block, successful anesthesia was achieved in only 63 percent of mandibular molars, 67 percent of premolars and 37 percent of incisors.⁴ The authors concluded that numbed lips and negative mucosal response may not indicate the onset of successful anesthesia.

In the studies described above, the mean onset time of sufficient anesthesia was eight to 17 minutes. Remarkably, there are few studies of the time elapsed from injection of a local anesthetic to the achievement of anesthesia before tooth extraction. In the only such

ABSTRACT

This article describes the clinical testing of a new system for the intraosseous delivery of local anesthesia. The author concluded that the system delivered local anesthetic very effectively (in some situations more effectively than the traditional delivery method), thus offering a great potential advantage to both dentists and patients.

study published in the past decade, Todorvic, Sajcic and Petrovic found this time to range from one to seven minutes following administration of a mandibular block.⁵ These authors observed that mucosal depression and anesthesia of the lip and tongue do not necessarily ensure a pain-free extraction.

Given such reports, as well as personal clinical experience with the vagaries of the inferior alveolar block, I undertook an evaluation of the Stabident System, which I purchased from the supplier—Fairfax Dental, Inc.—for \$99. The Stabident is an intraosseous injection system of delivering local

anesthetic (2 percent lidocaine hydrochloride and 1:100,000 epinephrine). In the product literature, the manufacturer of this delivery system claims that it provides “instant anesthesia” and ensures “a totally pain-free procedure.” Although one non-refereed account has been published regarding the efficacy of the Stabident System in restorative dentistry,⁶ no account has been published regarding its efficacy in exodontia. The objectives of the study were:

- to measure the time elapsed between injection and achievement of anesthesia profound enough to allow extraction of a tooth;
- to determine the number of cartridges of anesthetic necessary to induce such anesthesia using the Stabident System;
- to evaluate the system’s general efficacy.

MATERIALS AND METHODS

The Stabident System is a resurrection, with contemporary armamentarium, of the intraosseous system that enjoyed a brief period of popularity in the 1970s.⁷⁻¹³ Other systems have used either a bur or reamer to perforate the cortical plate. The Stabident System uses a perforator and

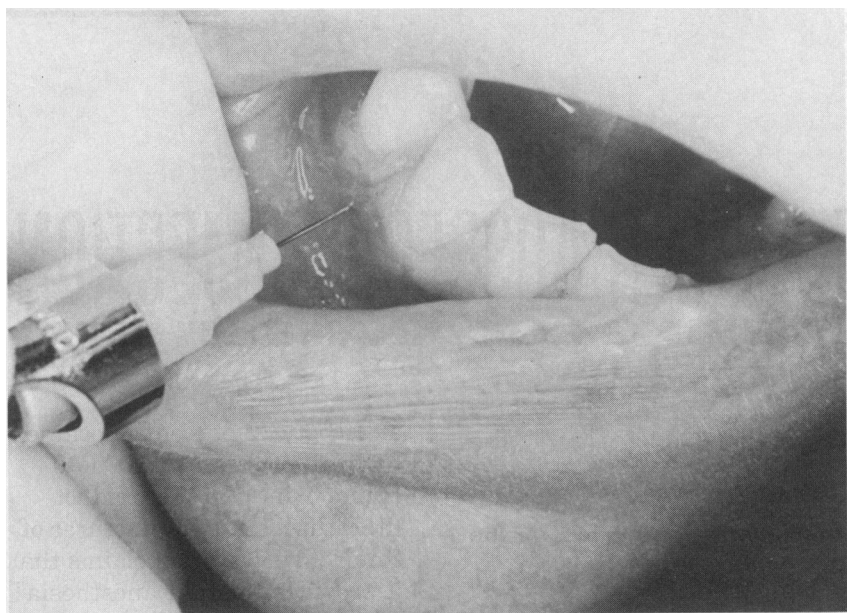


Figure 1. Site of mucosal anesthesia.

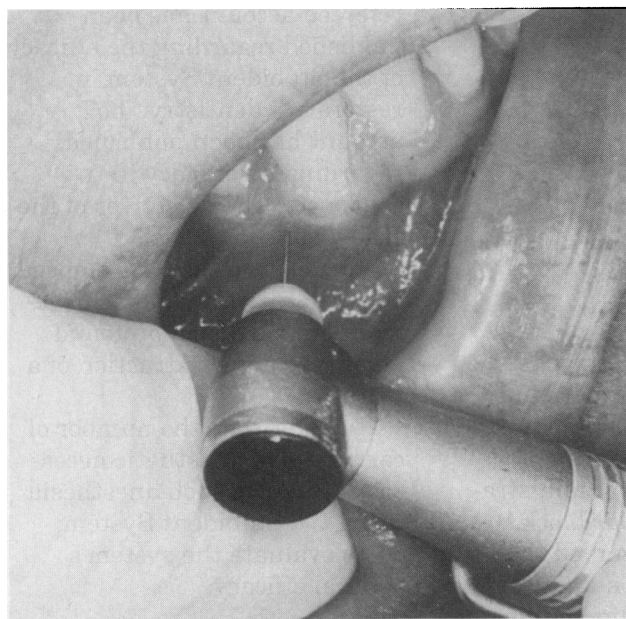


Figure 2. Injection into cancellous bone.

injector needle. The perforator is a 9-millimeter-long solid 27-gauge needle driven by a contra-angle handpiece. The system's injector needle (assembled with a standard cartridge and syringe) is a standard 27-gauge needle for a syringe (0.40 mm in diameter) but is much shorter than the

0.5 centimeters from the gingival margin and between the roots of the teeth. The injector needle is used to inject ≤ 0.2 milliliters of anesthetic solution (the same 2 percent lidocaine hydrochloride and 1:100,000 epinephrine as delivered by traditional methods) into the mucosa (Figure 1). When the

mucosa has been anesthetized (as determined by reaction to pressure created with a periosteal elevator), the Stabident perforator is used to drill a hole through the cortical plate and just into the interosseous bone (Figure 2). Generally, the perforation is made distally to the tooth to be extracted. The injection needle then is inserted into the hole, and the remainder of solution of the same local anesthetic in the cartridge is injected into the cancellous bone (Figure 3).

Baseline measurements on controls. To establish a baseline, we recorded results on a random consecutive series of patients undergoing exodontia and receiving anesthesia through traditional techniques. Fifty maxillary molars and premolars and 50 mandibular molars and premolars were anesthetized in the usual manner, as controls. In all cases, we recorded the number of cartridges of local anesthetic used and the time necessary to achieve anesthesia (determined by reaction to deep pressure created with a periosteal elevator). All injections and extractions were carried out by first- or third-year residents or staff in oral and maxillofacial surgery. No attempts were made to determine inter-practitioner differences in technique. All patients were given routine analgesics after surgery, usually about 10 or 12 tablets of acetaminophen (Tylenol 3 [McNeil Consumer] or Vicodin [Knoll]) over a period of two to three days.

First study group. Next, I studied a random consecutive series of 75 patients anesthetized through use of the Stabident System. Of our five

operatories, only two are equipped with handpieces that would permit us to use the perforator; thus, the next 75 patients who used those two operatories participated in this study group. All patients signed informed consent forms that had been approved by the human subjects research committee at Hennepin County Medical Center. We purchased the materials used with this group at the regular retail price. We made no attempt to discover the duration of anesthesia administered using the Stabident System, but we were able to work as long as 15 minutes without difficulty. Patients experienced no anesthesia of lips or tongue, intraoperatively or postoperatively.

Second study group. I then studied a subsequent random series of 89 patients entering the two Stabident-equipped operatories; these cases involved the removal of 116 teeth. As with the first group, all materials used with this group were purchased at the regular retail price. Also as with the first group, we did not gauge the duration of anesthesia administered using the Stabident System, but we were able to work as long as 15 minutes without difficulty. Patients experienced no anesthesia of lips or tongue, intraoperatively or postoperatively.

RESULTS

Controls. Figures 4 and 5 show the number of cartridges of 2 percent lidocaine and 1:100,000 epinephrine used and the time needed for effective anesthesia delivered to the control subjects by traditional methods. Not surprisingly, the mandibular teeth took longer to anesthetize,

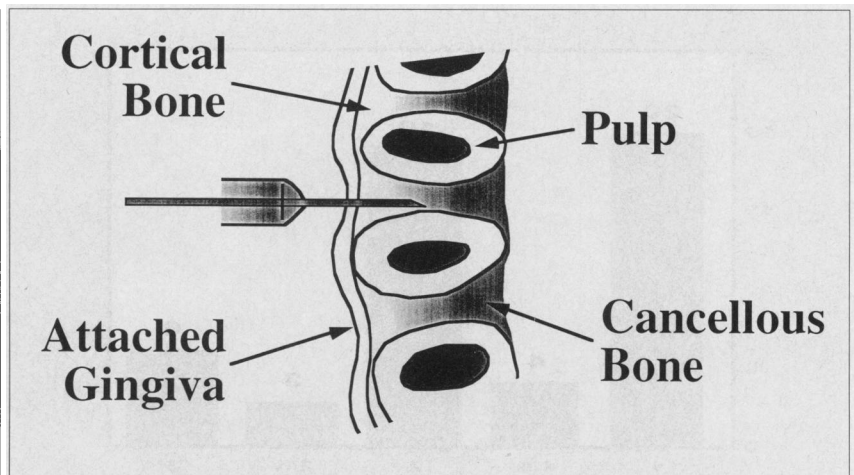


Figure 3. Diagram of interosseous bone.

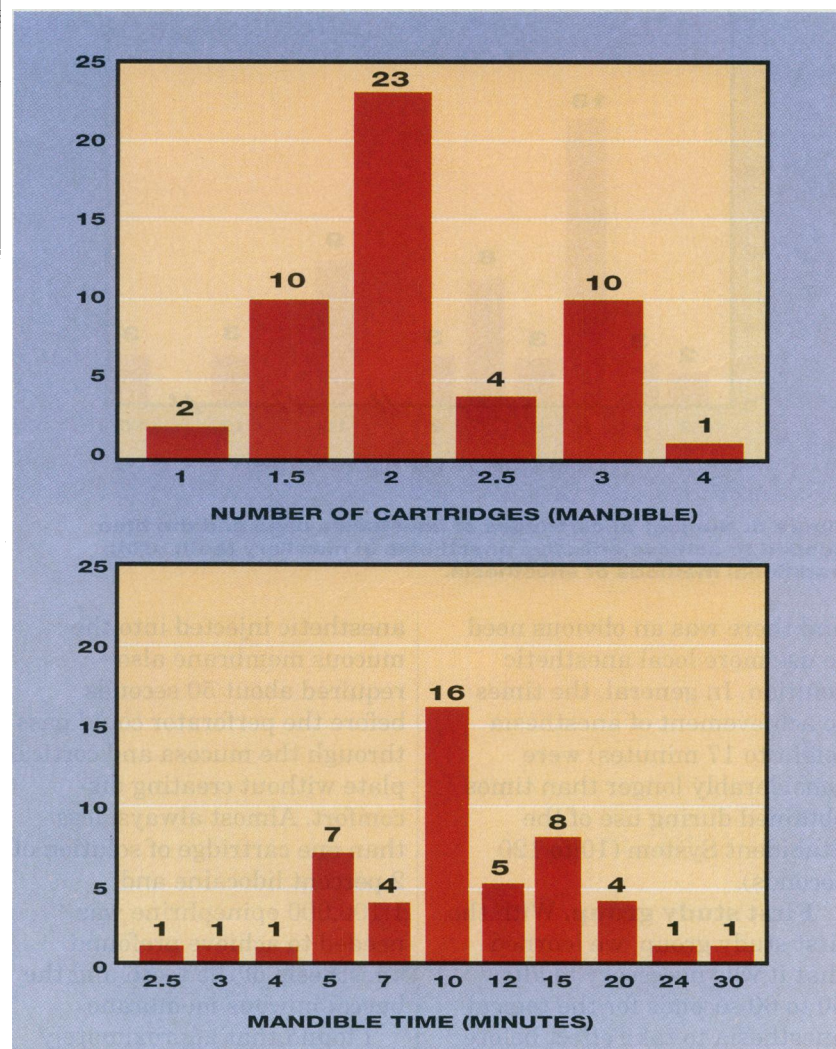


Figure 4. Number of cartridges of anesthesia used and the time needed to achieve effective anesthesia in mandibular teeth using traditional methods of anesthesia.

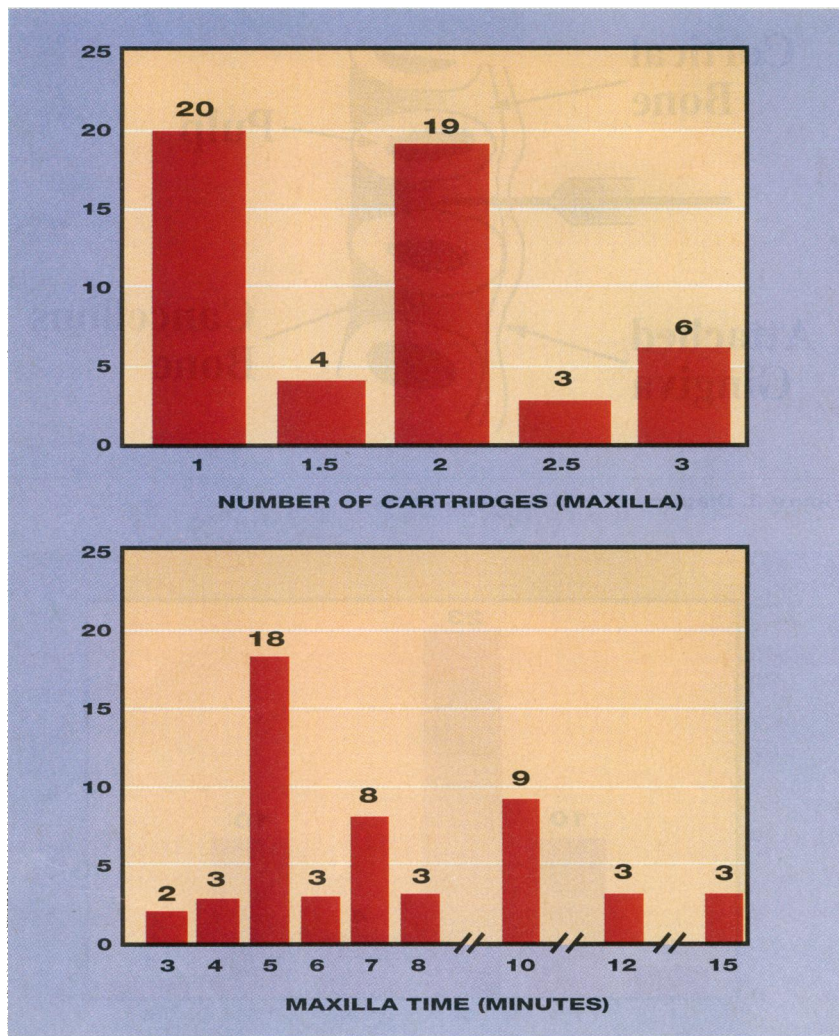


Figure 5. Number of cartridges of anesthesia used and the time needed to achieve effective anesthesia in maxillary teeth using traditional methods of anesthesia.

and there was an obvious need to use more local anesthetic solution. In general, the times to achievement of anesthesia (eight to 17 minutes) were considerably longer than times obtained during use of the Stabident System (10 to 120 seconds).

First study group. With the first study group, we learned that it was necessary to allow 50 to 60 seconds for the topical anesthesia to take effect before using the perforator; it was rarely effective at under 45 seconds. The small amount of

anesthetic injected into the mucous membrane also required about 50 seconds before the perforator could pass through the mucosa and cortical plate without creating discomfort. Almost always, less than one cartridge of solution of 2 percent lidocaine and 1:100,000 epinephrine was needed to achieve profound anesthesia of the tooth and the buccal mucous membrane.

I found that approximately 0.2 to 0.4 mL of local anesthetic solution should be injected into the lingual or palatal cuff of

tissue adjacent to the tooth about to be extracted. Subsequently, I learned that it was possible to dispense with that palatal injection. With the Stabident System, there were no more than two or three instances in which a small part of an additional cartridge of local anesthetic had to be delivered. Those cases required the additional anesthetic primarily because 0.5 cc or more of the solution had been used in the submucosal injection, and I felt that there might not be sufficient solution left for the intraosseous injection.

If deep post-injection pressure with the periosteal elevator provoked no response, the tooth was held to be anesthetized and ready for extraction. The time lapse between completing the injection and commencing the extraction procedure was rarely more than 15 seconds and was often just 10 seconds. Injection of one patient's no. 13 tooth took less than 5 seconds, and another patient's no. 30 tooth was apparently instantaneously anesthetized.

A large majority of the extractions were accomplished under excellent anesthesia provided by the Stabident System. In other words, the patients did not even know when the extraction was done, including one patient with an abscess and another who was resistant to three other alveolar blocks. Four extractions had very good anesthesia (one patient felt pressure only in teeth nos. 10 and 11, and two other patients felt only pressure, one in tooth no. 19 and another in tooth no. 30); two had acceptable anesthesia (one patient in tooth no. 19, another

in tooth no. 6). One patient complained of discomfort (in tooth no. 27), even though tests for sensation were negative; another patient complained of pain upon injection of tooth no. 30. Eleven applications were thwarted by broken needles or inability to insert the needle through the bore hole (see Discussion, below). There was only one case of dry socket in the first group studied. None of these patients experienced anesthesia nor subsequent paresthesia of lips and tongue with anesthetic administered by the Stabident System.

Second study group. In Group 2, five extractions each required nearly two cartridges of 2 percent lidocaine and 1:100,000 epinephrine to obtain satisfactory anesthetization, and there were four failures with the technique (inability to deliver the anesthetic into the intraosseous bore hole, necessitating use of traditional methods of delivery). In these four cases, the diameters of the perforators were 0.40 or 0.41 mm. The remaining 80 extractions were accomplished with ease and to great patient satisfaction (as expressed by the patients themselves). No third molars were removed. There was only one case of dry socket in this group as well. A few patients in both groups experienced some discomfort as the perforator went into the cancellous bone. It is unclear why this would be, as the nerve supply within cancellous bone is restricted to the blood vessels and is most likely to be sympathetic, controlling the diameter of the vessels rather than pain fibers. However, the type of nerve activity in cancellous bone is not known

with certainty, and it may well be that cancellous bone does contain pain fibers. In the vast majority of patients in Group 2, it was not difficult to inject the fluid slowly into the cancellous bone. In a number of patients, however (about 10), considerable strength was required to inject the solution. The injection was discomforting for three patients, one of whom found the injection very painful.

DISCUSSION

After a number of failed attempts to insert the injector needle through the hole created by the perforator, I measured the diameter of 30 perforators and injector needles. The usual 27-gauge injection needle has a diameter of 0.40 mm (0.016 inches). Among the 30 perforators measured, three had a diameter of 0.39 mm; the other 27 had a diameter of 0.40 mm. Most of the 30 injector needles measured 0.40 mm in diameter, but some were as large as 0.44 mm.

Because of potential incompatibility in size between the perforator and the injector needle, I was reluctant to try the system on a second molar, as access to a site posterior to the tooth would be too difficult with the syringe—particularly if one could not be sure whether the injector needle would fit into the hole created by the perforator. The inventor—Frank Dillon, D.D.S.—has suggested bending the needle (telephone communication, early 1994), and on occasion I did this. Nevertheless, it was frustrating to fail to gain entry into the bore hole due to a lack of precision in the diameters of the perforator and the injector needle. This lack of precision is

due entirely to the limits of tolerance that at present govern the manufacture of needles.

To address this problem, the supplier (Fairfax Dental) suggested that the size of the perforator be increased. The only concern about this was that it could lead to a backflow of the anesthetic solution and thus not allow a sufficient concentration of solution to gather about the apex of the tooth. I decided to test this assumption by using perforators of 0.45 mm, 0.44 mm, 0.43 mm, and 0.42 mm while continuing to use a needle of 0.40 mm. Needle entry into the bore hole became much easier when I used perforators of 0.43 mm and 0.44 mm, so I dispensed with using the 0.45 mm perforator.

Therefore, I tried an additional 80 needles at 0.4 mm diameter and perforators at 0.43 mm diameter. In this cohort, there were no incidents of high-pressure resistance when the solution was injected. The needle entered the bore hole easily, and the procedure was much easier. The suppliers subsequently began to use 0.4 mm needles and 0.43 mm perforators. In Group 2, there were three occasions when we had to resort to the traditional lingual block technique. No explanation presents itself for the failure, in those cases, to attain adequate anesthesia with the intraosseous system.

Though the inventor uses an injection between the maxillary bicuspid and between the mandibular bicuspid to anesthetize the anterior teeth prior to restorative work,¹⁴ we have had an insufficient number of such cases to determine whether this holds true for the extraction of the

anterior teeth. In the two or three anterior maxillary cases, this kind of anesthetization has proven effective. We used the Stabident System with great success in patients who were resistant to anesthesia after having three or four cartridges of solution injected before extraction of mandibular molars. In a few patients who told us, "Novocain doesn't work on me," the Stabident System provided immediate and profound anesthesia with an ordinary solution of 2 percent lidocaine and 1:100,000 epinephrine.

CONCLUSIONS

The Stabident System provides some considerable advantages, once the practitioner is skilled in using this system of delivering local anesthetic.

- The system allows a much-reduced time between injection of the anesthetic and the achievement of anesthesia. Even allowing 60 seconds for topical anesthesia, 60 seconds for infiltration of the mucous membrane and 30 seconds for injection of the solution, we found that rarely more than 3 to 3½ minutes were required before extraction could begin. In restorative work, this would

markedly reduce the downtime between injection and preparation of the tooth.


- Less local anesthetic is required than is used in traditional delivery methods; one cartridge is usually all that is necessary.

- The lips and tongue are not anesthetized. In the patient who is undergoing restorative work, this decided benefit allows for bilateral mandibular restorative work.

- Patients appreciate this system. A surprising number of the patients in the study vigorously expressed their appreciation of and gratitude for the painless nature of the injection and the speed of the procedure.

- Anterior maxillary anesthesia is possible without the usual injection in that area. This will be a boon to all patients.

- No palatal injection is needed. ■



Myer S. Leonard, D.D.S., M.D., is Division Head, Oral and Maxillofacial Surgery, Dentistry Department, Hennepin County Medical Center, and Professor of Oral and Maxillofacial Surgery, University of Minnesota, Minneapolis. Address reprint requests to Dr. Leonard, 825 S. 8th St., Suite 260, Minneapolis, Minn. 55404.

The opinions expressed or implied are strictly those of the author and do not necessarily reflect the opinions or official policies of the American Dental Association.

Neither the author nor the American Dental Association has any commercial interest in the products mentioned.

1. Kaufman E, Weinstein P, Milgrom P. Difficulties in achieving local anesthesia. *JADA* 1984;108:205-8.
2. Dreven LJ, Reader A, Beck FM, Meyers WJ, Weaver J. An evaluation of an electric pulp tester as a measure of analgesia in human vital teeth. *J Endod* 1987;13:233-8.
3. White JJ, Reader A, Beck M, Meyers WJ. The periodontal ligament injection: a comparison of the efficacy in human maxillary and mandibular teeth. *J Endod* 1988;14:508-14.
4. McLean C, Reader A, Beck M, Meyers WJ. An evaluation of 4% Prilocaine and 3% Mepivacaine compared with 2% lidocaine for inferior alveolar nerve block. *J Endod* 1993; 19:146-50.
5. Todorvic L, Stajcic Z, Petrovic V. Mandibular versus inferior dental anesthesia: clinical assessment of three different techniques. *Int J Oral Maxillofac Surg* 1986;15:733-8.
6. Canavan DW. Clinical impressions of the Stabident local anaesthesia system. *Dent Pract* 1992.
7. Magnes GD. Intraosseous anesthesia. *Anesth Prog* 1968;15:264-7.
8. Bourke K. Intra-osseous anesthesia. *Dent Anesth Sedat* 1974;8:13-9.
9. Lilienthal B. A clinical appraisal of intraosseous dental anesthesia. *Oral Surg Oral Med Oral Pathol* 1975;39:692-7.
10. Cannell M, Cannon PD. Intraosseous injections of lignocaine local anesthetics. *Br Dent J* 1976;141:48-50.
11. Pearce JH. Intraosseous injection for profound anesthesia of the lower molar. *J Colo Dent Assoc* 1976;54:25-6.
12. Biddulph WG. Intraosseous anesthesia for dental procedures. *Ariz Dent J* 1976;22:16-7.
13. Garfunkel AA, Kaufman E, Marmary Y, Galeli D. Intraligamentary-intraosseous anesthesia: a radiographic demonstration. *Int J Oral Surg* 1983;12:334-9.
14. Dillon F. Stabident [video]. London, England: Video Insight;1991.